

The book was found

Ekgs / Ecgs (Quick Study: Academic)

Quick Study ACADEMIC **EKGs / ECGs** Copyrighted Material

Basics

- The abbreviation EKG comes from the German word *elektrokardiogramm*; both EKG and ECG can be used to mean "electrocardiogram". However, EKG will be used throughout this guide.
- An EKG is a recording of the heart's electrical activity. This activity is produced by cardiac cells.
- There are two basic types of cardiac cells: myocardial cells and specialized cells.
- Myocardial cells are the working machinery of the heart and comprise the majority of heart tissue. They form the muscular base of the atria and ventricles of the heart.
- Myocytes bundle these cells side by side, causing the cells to contract.
- Specialized cells are the conduction system of the heart.
- Pacemaker cells generate and regulate myocardial cells; they do not contract themselves, so they cannot contract. They generate and conduct electrical impulses throughout the heart.
- Electrical conducting cells conduct impulses generated by pacemaker cells throughout the heart, but are not functioning of the heart.
- In a cardiac cell's resting state, the inside of the cell is negatively charged when compared to the outside of the cell; the electrochemical inside the cell is maintained by ion pumps on the cell membrane.
- These pumps control the distribution of electrolytes, such as potassium, sodium, chloride, and calcium ions, which are vital to maintaining the negative polarity inside the cell.
- The measurement of the difference in electrical charge on either side of a cell membrane is called **action potential**.
- The change of electrolyte through the cardiac cell membrane produces this electrical activity.
- When cardiac cells lose their negative polarity, depolarization occurs. **depolarization** is an electrical event caused by positively charged ions opening the cell membrane.
- Depolarization is transmitted from cell to cell, producing a wave of electrical activity across the heart, which can be recorded by electrode placement on a patient's skin. Depolarization initiates the cycle of cardiac contraction.
- Depolarization is followed by reversal of the flow of ions across the cell membrane called **repolarization**, which is the restoration of negative polarity inside the cell.
- Repolarization initiates the relaxation phase of cardiac muscle, which is also detected by electrodes placed on the chest.


Conduction Pathway

- The path of conduction begins at the **sinoatrial (SA) node**, or **sinus node**, whose job is to pace the heart; generally, the sinoatrial pacemaker cells are located in the SA node.
- These cells have the slowest firing rate (approx. 100-110 bpm) but can vary tremendously based on the demands placed on the heart, such as exercise.
- The signal is then sent to the **atrioventricular (AV) node**, located in the lower area of the right atrium.
- The main function of the AV node is to delay the electrical impulses; this allows for the atria to contract and ventricles to fill before they contract.
- The impulses are then transmitted through the **bundle of His**, located in the upper part of the septum that separates the ventricles.
- The bundle of His has pacemaker cells that can transmit at a rate of 40-100 bpm.
- This area connects the AV node with the right and left bundle branches—an area called the **AV junction**.
- The right bundle branch sends messages to the right ventricle; the left bundle branches divide and supply transmission to the left ventricle.
- The right and left bundle branches divide into smaller branches and connect to the Purkinje fibers, which penetrate the myocardial muscle, where electrical impulses are sent through the Purkinje fibers, to cause ventricular contraction.
- These fibers have pacemaker cells that have an intrinsic pace of 20-40 bpm.

100 bpm = beats per minute

Electrocardiogram

- An EKG is recorded by electrodes (leads) which pick that are placed on the patient's chest.
- Several electrodes are placed on the chest to view the heart from different angles; a **lead** is a view of the heart from a particular angle.
- A single EKG can be done with three electrodes known as lead I, lead II, and lead III.
- An EKG records the electrical activity between the electrodes.
- The electrodes are often color-coded: black, white, and red.
- One electrode is positive, the second is negative, and the third is the "ground" which minimizes electrical interference from other sources.
- When electricity flows toward the positive electrode, the pattern on the graph will be upright.
- Consequently, when electricity flows away from the positive electrode, the pattern will appear downward.



12-Lead EKG

- Provides three angles of the heart because it utilizes 12 leads: I, II, III, aVR, aVL, aVF, V1, V2, V3, V4, V5, and V6.
- The 12 leads are taken from 10 electrodes.
- Two electrodes are placed on each arm and each leg.
- Six precordial electrodes (V1-V6) are placed on the chest systematically.

Precordial Electrodes

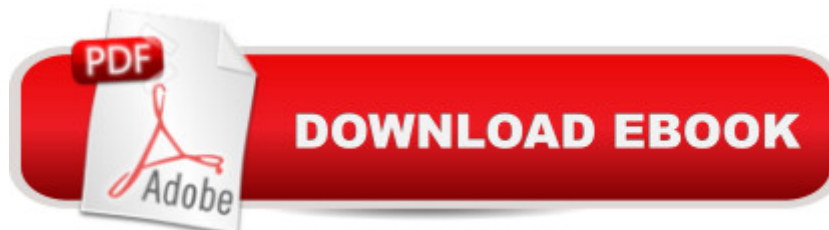

- V1 is placed in the 4th intercostal space to the right of the sternum and lies over the right ventricle.
- V2 is placed in the 4th intercostal space to the left of the sternum.
- V3 is placed between V2 and V4, which is located at the 5th intercostal space midclavicular line.
- V4 is placed between V3 and V6, which is located at the 5th intercostal space midaxillary line.
- V5 is placed at the 5th intercostal space midclavicular line.

Augmented Leads

- There are three augmented limb leads, which are created by making one electrode positive and the others negative; for example:
- Lead aVR** is created by making the left arm positive and the other limbs negative.
- Lead aVL** is created by making the right arm positive and the other limbs negative.
- Lead aVF** is created by making the leg positive and the other limbs negative.
- The anterior part of the heart is viewed in leads V1, V2, and V3.
- The inferior part of the heart is viewed in leads II, III, and aVF.
- The left lateral side of the heart is viewed in leads I, aVL, V5, and V6.
- The right ventricular part of the heart is viewed in leads V1 and V2.

EKG Paper

- In order to view waveforms, it is necessary to understand EKG graph paper.
- The graph paper is made out of small and large squares.
- Each small square represents 0.20 second.
- There are five small squares in a large square; each large square represents 1.00 second.
- The large squares equal 1 second.
- The standard rate or speed of an EKG is 25 mm per second.
- The vertical lines on EKG paper measure the voltage or amplitude, which is the strength of the electrical current.
- A steady current will have a greater deflection than a weaker current.
- When calibrated correctly, one small square is 0.1 mV, which is equal to eight 1.1 millivolt calibration pulses, which is equal to five small squares. It is one large and equals 1.0 mV.



Synopsis

The newest edition to BarChartsâ™ line of medical guides is an essential companion for anyone studying EKGs/ECGs or working in the medical field. This guide features an introduction to EKGs and how they work and also includes detailed sections covering the main types of arrhythmias, such as sinus rhythms, atrial rhythms, junctional rhythms, ventricular rhythms, and heart blocks. Helpful illustrations, along with the rate, rhythm, P wave, PR interval, and QRS complex, of each rhythm covered are also included to help with identification.

Book Information

Series: Quick Study: Academic

Pamphlet: 6 pages

Publisher: QuickStudy; 1 Fol Lam edition (May 31, 2012)

Language: English

ISBN-10: 1423218620

ISBN-13: 978-1423218623

Product Dimensions: 8.5 x 11 x 0.1 inches

Shipping Weight: 2.4 ounces (View shipping rates and policies)

Average Customer Review: 4.7 out of 5 stars [See all reviews](#) (64 customer reviews)

Best Sellers Rank: #17,472 in Books (See Top 100 in Books) #3 in [Books > Medical Books > Allied Health Professions > Medical Technology](#) #12 in [Books > Medical Books > Medicine > Internal Medicine > Pathology > Diseases > Cardiovascular](#) #15 in [Books > Medical Books > Medicine > Internal Medicine > Cardiology](#)

Customer Reviews

I'm in PA school and EKGs, for whatever reason, have been a struggle for me. This handy little pamphlet has been a huge help. Everything is laid out very simply in one place. It takes a lot of the fluff out that some other sources include. Best of all, you can store it in a folder or binder so it's easy to bring with you wherever you need. The product is laminated so it's very sturdy and can take a reasonable amount of wear. A must buy!

The EKG - Quick Study guide was more than I thought. It had a lot of information. It gave me all the information I was looking for and more. It is very handy to carry around. I use it at work. The price was great !

Useful tool for review, I been off in nursing for awhile, this here helps me a lot to refresh my knowledge, it comes with a laminated material which it is not easily tore up, easy to carry, and good to keep on file!

My husband works as a heart monitor tech and used these to study for his certifications. Additionally, he has them at his station and says they are so good people are always borrowing them and training staff is looking into purchasing for position candidates as study tool.

Awesome, use it in my job to help in case I need a refresher. Love to have something easy to look at and reference if need be.

I used this to practice over my EKG basics before I took my certification exam and passed with flying colors...

This has been extremely helpful in my studies. You seek and find exactly what you're looking for without a long drawn out book explanation. Great for reference.

very helpful quick study guide. convenient and 14 more words required. blah blah blah blah.... well, this is a good quick guide for short time review

[Download to continue reading...](#)

Ekgs / Ecgs (Quick Study: Academic) Fast Facts About EKGs for Nurses: The Rules of Identifying EKGs in a Nutshell (Fast Facts (Springer)) Nclex-Rn Study Guide (Quick Study Academic) The Complete Guide to ECGs Deciphering Difficult Ecgs (Advanced Skills) ECGs for Nurses (Essential Clinical Skills for Nurses) Small Animal ECGs: An Introductory Guide Understanding EKGs: A Practical Approach (3rd Edition) EKGs for the Nurse Practitioner and Physician Assistant Memory Bank for Critical Care: Ekgs and Cardiac Drugs (The Jones and Bartlett Pocket-Sized Nursing Reference) Memory Bank for Critical Care: Ekgs and Cardiac Drugs Endocrine System (Quick Study Academic) Circulatory System Advanced (Quick Study: Academic) Medical Coding: Icd-10-Pcs (Quick Study Academic) The Foot (Quick Study Academic) Anatomy Test (Quick Study Guides-Academic) Spanish Grammar (Quick Study: Academic) Nursing Pharmacology (Quick Study: Academic) Nursing Math (Quick Study: Academic) Spanish Conversation (Quick Study: Academic)

[Dmca](#)